

## ARTICLE

# Neuronal cell types in the anterior ventral thalamic nucleus of the camel

Saleh M. Al-Hussain<sup>1</sup> | Shaden A. Albostanji<sup>2</sup> | Ayman G. Mustafa<sup>3,4</sup> | Sami Zaqout<sup>3,4</sup> 

<sup>1</sup>Faculty of Medicine, Department of Anatomy, Jordan University of Science and Technology, Irbid, Jordan

<sup>2</sup>Faculty of Applied Health Sciences, Hashemite University, Zarqa, Jordan

<sup>3</sup>Department of Basic Medical Sciences, College of Medicine, QU Health, Qatar University, Doha, Qatar

<sup>4</sup>Biomedical and Pharmaceutical Research Unit, QU Health, Qatar University, Doha, Qatar

## Correspondence

Sami Zaqout, Department of Basic Medical Science, College of Medicine, QU Health, Qatar University, Doha, Qatar.  
 Email: sami.zaqout@qu.edu.qa

## Abstract

The anterior ventral nucleus neurons in of the camel brain were morphologically studied by Golgi impregnation method. Two neuronal types of were found in the camel anterior ventral thalamic nucleus, namely, Golgi-type I neurons and Golgi-type II neurons. Those neurons were generally similar to their counterparts in the human thalamus. The Golgi-type I neurons exhibited medium to large cell body (mean diameter = 25  $\mu$ m) which was either multipolar or triangular in shape. They had from 3 to 10 primary dendrites with many branches but with no spines or appendages. The Golgi-type II neurons had small to medium size (somatic mean diameter = 17.5  $\mu$ m), their cell bodies were variable in shape, some were round, and others were multipolar or fusiform. These cells bodies had two to six primary dendrites with few branches that may have spines and/or grape-like appendages. Our findings shed some light on the anterior ventral thalamic nucleus structure of the camel as one of the strongest adaptive mammals to the hard climatic conditions.

## KEYWORDS

camel, thalamus, neurons, Golgi

## 1 | INTRODUCTION

Giving that the human brain anterior ventral thalamic nucleus (AV) was already studied in our laboratory (Al-Hussain Bani Hani, El-Dwairi, Bataineh, Al-Haidari, & Al-Alami, 2008; Hani, Al-Haidari, & Saboba, 2007); we decided to study this nucleus in the camel brain. The AV thalamic nucleus is located immediately posterior to the interventricular foramen as a thalamic tubercle. As a part of the limbic system, AV is the largest nucleus of the anterior group of the thalamic nuclei (Child & Benarroch, 2013; Grodd, Kumar, Schüz, Lindig, &

Scheffler, 2020). It has reciprocal connections with the hypothalamus mamillary body (Mammillo-thalamic tract) and with the cingulate gyrus (Child & Benarroch, 2013; Jankowski, Ronnqvist, Tsanov, et al., 2013).

The morphological features of neurons in various thalamic nuclei were described in many species by different studies (Al-Hussain, 1992; Al-Hussain & Kultas-Ilinsky, 1986; Braak & Braak, 1984; Braitenberg, Guglielmotti, & Sada, 1967; Fox, Ubeda-Purkiss, Ihrig, & Biagioli, 1951; Guillery, 1966; Hani et al., 2007; Kiss & Tömböl, 1972; Kuroda, López-Masaraque, &

This is an open access article under the terms of the Creative Commons Attribution License, which permits use, distribution and reproduction in any medium, provided the original work is properly cited.

© 2021 The Authors. *The Anatomical Record* published by Wiley Periodicals LLC. on behalf of American Association of Anatomists.

Price, 1992; Ma, Lynch, Donahoe, Attallah, & Rafols, 1998; Morest, 1975; Pearson & Haines, 1980; Rafols, Aronin, & Difiglia, 1987; Saini & Garey, 1981; Scheibel & Scheibel, 1966; Spreafico, Schmechel, Ellis Jr, & Rustioni, 1983; Tömböl, Ungváry, Hajdu, Madarász, & Somogyi, 1969; Winer, 1984; Yamamoto, Noda, Samejima, & Oka, 1985; Yen, Conley, & Jones, 1985). In the majority of these nuclei, two main types of neurons namely Golgi-type I and Golgi-type II were found. Medium to large sized Golgi-type I neurons had somatic mean diameter ranging from 20 to 40  $\mu\text{m}$  and having (1–6) primary dendrites with dense dendritic trees, protrusions and short hair like appendages for these dendrites. The smaller Golgi-type II neurons had somatic mean diameter ranging from 10 to 20  $\mu\text{m}$  with few (3–5) sparsely branching primary dendrites. These neurons had spines and grape-like dendritic appendages and their axons had local branches. The Golgi-type I were classified as thalamocortical projecting neurons (TCPN) (Pearson & Haines, 1980; Rafols et al., 1987; Saini & Garey, 1981; Tseng & Royce, 1986) while the Golgi-type II neurons were considered to be local circuit neurons (LCN) or interneurons (Ilinsky & Kultas-Ilinsky, 2001).

No small neurons (Golgi-type II) were found in one thalamic nucleus namely the dorsomedial nucleus (Ma et al., 1998). The same study reported that all of the neurons in the dorsomedial nucleus were large and considered as thalamocortical projection neurons. Another thalamic nucleus namely the anteroventral nucleus had been studied in both human (Hani et al., 2007) and cat (Somogyi, Tömböl, & Hajdu, 1973). In the human AV, two morphologically different types of neurons were found, one corresponded to Golgi-type I with large body and dense dendritic trees while the other type corresponded to Golgi-type II with small body, few branches and grape-like dendritic appendages. Although long segments of the axons of these small neurons were impregnated in one study (Hani et al., 2007), no local axonal branches were found. This may indicate that these neurons could be in fact thalamocortical projecting neurons rather than interneurons which come in agreement with the result of the other study (Somogyi et al., 1973). Finally, in another group of thalamic nuclei namely the intralaminar nuclei, denser dendritic trees were found in Golgi-type II neurons compared to Golgi-type I neurons (Hazlett, Dutta, & Fox, 1976; Tömböl, Bentivoglio, & Macchi, 1990; Tseng & Royce, 1986).

The aim of this study is to describe the microscopic features of different neuronal types in the camel thalamic AV nucleus and compare these neurons with their counterparts previously described in different thalamic nuclei in human and some other species. Hopefully, these

results will contribute to our understanding of the comparative neuroanatomy.

## 2 | MATERIALS AND METHODS

The Golgi-Kopsch method of silver impregnation method was used. This method usually stains between 1 and 5% of neurons without overlapping between the stained neurons. This enabled us to study the different parts of neurons including their spines and appendages.

Camel brains were bought from local butchery stores. No animals were sacrificed in this study, therefore Institutional Animal Care and Use Committee (IACUC) approval was waived. Two modifications of Golgi-Kopsch impregnation were carried out on seven well-fixed camel brains (fixed in 10% formalin for 1–3 months). Coronal blocks containing the AV thalamic nucleus were cut and processed according to:

### 2.1 | Fox, et al. (1951) modification

Block (4 mm thick) containing the AV thalamic nucleus was cut, dried, and kept in a mixture of 3% Zink chromate and 2% formic acid for 7 days. Then the block was removed from the chromate solution, dried without washing, and immersed in a 0.75% silver nitrate solution for another 7 days. This method gave the best results regarding the impregnation of axons of Golgi-type II neurons, impregnation of very few neurons with a very clear background.

### 2.2 | Braitenberg et al. (1967) modification

Blocks (about 2 mm thick) containing the anterior ventral nucleus of the thalamus were cut, dried and placed in a mixture of 3% potassium dichromate, 0.5% formaldehyde, and 12.5% sucrose for 12 days. Then they were incubated in a 0.75% silver nitrate solution for 7 days.

### 2.3 | Sectioning and mounting

The blocks of the two modifications were removed from the silver nitrate, and then cut into 100  $\mu\text{m}$  thick sections using a sliding microtome. The sections were kept in absolute alcohol in their original serial order for 2 hr before transferring them to xylene for clearing where they were kept for 5 min. Sections were mounted on

slides using DPX mounting medium and then slides were covered with cover slips.

## 2.4 | Drawing and photographs


Selected well-impregnated neurons were studied under Nikon light microscope equipped with camera Lucida (drawing tube), oculometer, and imaging system.

## 3 | RESULTS

Two types of neurons, namely Golgi-type I (TCPN) and Golgi-type II neurons (LCN) were found in the camel AV nucleus. These cell classes were distinguished by the soma size, density of the dendritic tree, and the dendritic appendages.

### 3.1 | Golgi-type I neurons (TCPN)

These neurons (Figure 1) had medium to large cell body with diameter range from 18 to 34  $\mu\text{m}$  with mean diameter = 25  $\mu\text{m} \pm 4.5$  ( $n = 20$ ). Their cell bodies exhibited primarily multipolar shape and sometimes they may be triangular with no spines or appendages. They had from 3 to 10 primary dendrites. These dendrites had no spines or appendages. The dendrites of these cells showed rich arborizations with two branching patterns (radiating and tufted). The radiating branching pattern was more common than the tufted one. The tufted pattern was seen more often in the proximal dendrites



**FIGURE 1** (a) Photomicrograph and (b) drawing of Golgi-type I neuron (X for drawing = 700)


comparing to the distal dendrites, which exhibited more radiating pattern.

### 3.2 | Golgi-type II neurons (LCN)

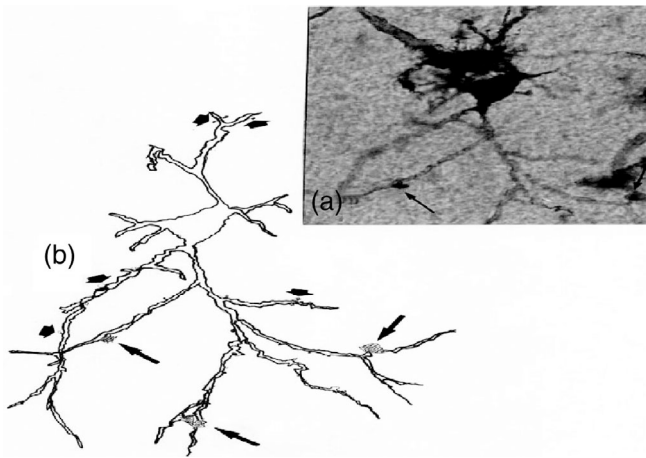
Golgi-type II neurons (Figures 2–4) represented the most frequent impregnated cell type in this study. These cells had small to medium size with somatic diameter range from 8 to 24  $\mu\text{m}$  with mean diameter = 17.5  $\mu\text{m} \pm 4.7$  ( $n = 20$ ). Their cell bodies may be round, multipolar, or fusiform in shape. These neurons had few (2 to 6) primary dendrites with less dense dendritic trees comparing to Golgi-type I neurons. In this study, Golgi-type II neurons were divided in two subtypes:

Golgi-type IIa (Figure 2) had round cell body and scarce primary dendrites (one to three). These dendrites were sparsely branching and had no spines or appendages. Golgi-type IIb (Figures 3 and 4) neurons had round, multipolar or fusiform cell body. They possessed dendritic tree of moderate density consisting of three to six primary dendrites.

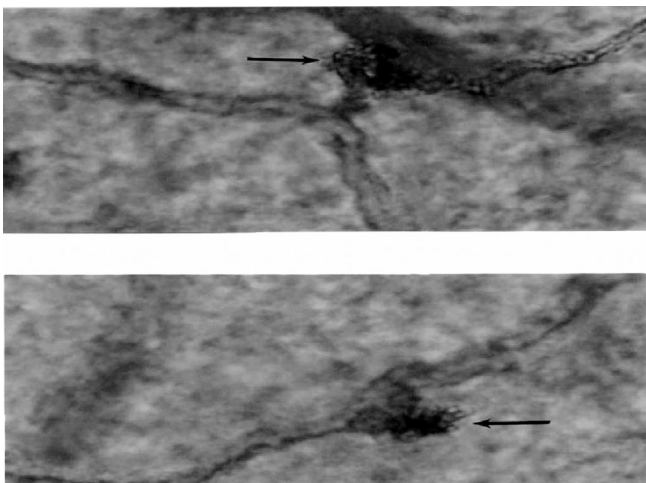
The dendrites of Golgi-type IIb neurons may have spines and/or grape-like appendages (Figures 3b and 4). Moreover, these dendrites had two branching patterns, the radiating and the tufted. The radiating branching pattern was clearly more common than the tufted. The tufted pattern was less common in Golgi-type IIb than Golgi-type I neurons. Proximal parts of the axons of Golgi-type IIb neurons were impregnated with no branches for these parts of the axons.



**FIGURE 2** (a) Photomicrograph and (b) drawing of Golgi-type IIa (X for drawing = 735)



**FIGURE 3** (a) Photomicrograph and (b) drawing of Golgi-type IIb neuron with grape-like appendages (long arrows) and spines (short arrows; X for drawing = 529). The arrows shown in the photomicrograph (a) indicate to two grape-like appendages shown on higher magnification in Figure 4



**FIGURE 4** Two photomicrographs of two grape-like appendages (arrows) of Golgi-type II neurons that shown in Figure 3a

## 4 | DISCUSSION

In this study, two main types of nerve cells were described in the camel AV thalamic nucleus and compared with their counterparts in other thalamic nuclei described in previous similar Golgi studies in human and other animals.

Golgi-type I nerve cells found in this study were found to be generally similar to their counterparts previously described in other thalamic nuclei including the human anterior ventral, ventral anterior, ventral posterior, ventral lateral nuclei as well as medial geniculate, and lateral geniculate bodies (Al-Hussain Bani Hani

et al., 2008; Braak & Braak, 1984; Grodd et al., 2020; Hajdu, Hassler, & Somogyi, 1982; Hani et al., 2007; Hazlett et al., 1976; Pearson & Haines, 1980; Schaltenbrand & Wahren, 1977; Tseng & Royce, 1986). In all these studies, Golgi-type I nerve cells were found to have medium to large cell bodies and dense dendritic trees. In this study, Golgi-type I neuronal cell bodies were not seen to have any spines or appendages. These results are in line with similar findings reported in many previous studies (Al-Hussain, 1992; Babb, 1980; Pearson & Haines, 1980) but contradicted with the results reported in the centromedian-parafascicular complex of the monkey (Hazlett et al., 1976). The authors of the last study reported cell bodies of Golgi-type I neurons with spines and appendages. Like their counterparts in the human AV nucleus (Al-Hussain Bani Hani et al., 2008; Hani et al., 2007), the dendrites of these neurons have both radiating-tufted dendritic branching patterns but with no dendritic spines or hair-like appendages. A combined horseradish peroxidase (HRP) staining and electrophysiological study on the AV thalamic nucleus in cats identified relay, projection and interneurons (Yamamoto et al., 1985). The study distinguished three types of dendritic patterns (radial, tufted, and linear-oriented) in the relay and projection neurons. The first two patterns are in line with dendritic pattern in Golgi-type I neurons described in our present study and in other study conducted in cats (Kiss & Tömböl, 1972). Electrophysiological experiments confirmed that these neurons are relay neurons in the thalamus (Yamamoto et al., 1985).

Golgi-type II nerve cells were found to have both similarities and differences comparing with their counterparts already reported in other thalamic nuclei. Like Golgi-type II neurons described in other studies (Al-Hussain, 1992; Tömböl et al., 1969), these neurons were found in this study to have small to medium cell body. No somatic spines or appendages. This was in line with similar results reported in several species but contradicted with results reported in two previous studies (Al-Hussain, 1992; Hazlett et al., 1976) who reported such somatic spines and appendages. Golgi-type II nerve cells showed grape-like appendages. The grape-like appendage was found to be a part of complicated synaptic structures known as glomeruli that were mentioned in previous study (Morest, 1975). In those glomeruli, dendrites receive synapses from afferent fibers and make synapses on dendrites of Golgi-type I cells (Al-Hussain, 1992). The grape-like appendages in this nucleus were detected not only along the shaft of dendrites like those reported for the Golgi-type II cells in the motor thalamic nuclei of the cat (Somogyi et al., 1973; Tömböl et al., 1990; Tseng & Royce, 1986) and humans (Al-Hussain, 1992) but also at dendritic tips. Concerning the axons of Golgi-type II cells,

there were no branches found for the impregnated part. Whether or not these axons had any branches like the axons of Golgi-type II cell in the motor thalamic nuclei of the cat (Somogyi et al., 1973; Tömböl et al., 1990; Tseng & Royce, 1986), or those that found in the dorsal lateral geniculate body of the Macaca monkey (Wilson & Hendrickson, 1981) was difficult to determine. If these axons of the camel brain thalamic AV nucleus were really with no branches, this may make them functionally different from their counterparts in other thalamic nuclei mentioned above. Special interest is the absence of these branches in the long segment of the Golgi-type II axons that were impregnated in the human AV nucleus (Al-Hussain Bani Hani et al., 2008; Hani et al., 2007). Therefore, these axons might make synapses with cells away from their native cells within the AV nucleus itself or in other thalamic nuclei or they might also be projecting to areas out of the thalamus such as the cerebral cortex. In fact, some neurons in the lateral geniculate body with morphological features similar to Golgi-type II neurons were found to be projection neurons (Pearson & Haines, 1980).

Our results will be an addition to our previous findings on the gracile and cuneate nuclei (Al-Hussain, Al-saffar, & Zaqout, 2012; Zaqout, Al-Hussain, Al-Saffar, & El-Dwairi, 2012) and shed some light on the neuronal structures in different brain regions of the camel. Collectively, these findings illustrate part of the adaptive mechanisms developed in camel as one of the species living in hard climate conditions. This will open the door for further investigations using immunohistochemistry and electron microscopy techniques to dissect the neuronal subtypes in different brain regions of the camel.

## ACKNOWLEDGMENTS

Open Access funding provided by the Qatar National Library

## CONFLICT OF INTEREST

The authors declare no conflict of interest.

## AUTHOR CONTRIBUTIONS

**Saleh Al-Hussain:** Conceptualization; formal analysis; methodology; project administration; resources; supervision; writing-original draft; writing-review and editing. **Shaden Albostanji:** Formal analysis; investigation; methodology; validation; visualization; writing-original draft. **Ayman Mustafa:** Conceptualization; investigation; resources; writing-review and editing. **Sami Zaqout:** Funding acquisition; resources; writing-original draft; writing-review and editing.

## DATA AVAILABILITY STATEMENT

The datasets used and/or analyzed during the current study are available from the corresponding author on reasonable request.

## ORCID

Sami Zaqout  <https://orcid.org/0000-0002-3298-4425>

## REFERENCES

- Al-Hussain Bani Hani, S. M., El-Dwairi, Q. A., Bataineh, Z. M., Al-Haidari, M. S., & Al-Alami, J. (2008). Golgi-type I and Golgi-type II neurons in the ventral anterior thalamic nucleus of the adult human: Morphological features and quantitative analysis. *Cellular and Molecular Neurobiology*, 28(3), 411–416. <https://doi.org/10.1007/s10571-007-9248-8>
- Al-Hussain, S. M. (1992). Morphological characteristics of different types of neurons in the ventrooralis anterior, ventrooralis internus, and ventrooralis posterior nuclei in the human thalamus. *Cellular and Molecular Neurobiology*, 12, 217–224. <https://doi.org/10.1007/BF00712927>
- Al-Hussain, S. M., & Kultas-Ilinsky, K. (1986). Cytological characteristics of two types of local circuit neurons in the motor thalamus of adult cat. *Social Neuroscience*, 11, 35.
- Al-Hussain, S. M., Al-Saffar, R. A., & Zaqout, S. I. (2012). Morphological and quantitative study of neurons in the gracile nucleus of the camel brain stem. *Journal of Behavioral and Brain Science*, 2, 35–47. <https://doi.org/10.4236/jbbs.2012.21005>
- Babb, R. S. (1980). The pregeniculate nucleus of the monkey (Macaca mulatta). I. A study at the light microscopy level. *The Journal of Comparative Neurology*, 190(4), 651–672. <https://doi.org/10.1002/cne.901900404>
- Braak, H., & Braak, E. (1984). Neuronal types in the lateral geniculate nucleus of man. A Golgi-pigment study. *Cell and Tissue Research*, 237(3), 509–520. <https://doi.org/10.1007/BF00228435>
- Braitenberg, V., Guglielmotti, V., & Sada, E. (1967). Correlation of crystal growth with the staining of axons by the Golgi procedure. *Stain Technology*, 42(6), 277–283. <https://doi.org/10.3109/10520296709115026>
- Child, N. D., & Benarroch, E. E. (2013). Anterior nucleus of the thalamus: Functional organization and clinical implications. *Neurology*, 81(21), 1869–1876. <https://doi.org/10.1212/01.wnl.0000436078.95856.56>
- Fox, C. A., Ubeda-Purkiss, M., Ihrig, K., & Biagioli, D. (1951). Zinc chromate modification of the Golgi technic. *Stain Technology*, 26(2), 109–114. <https://doi.org/10.3109/10520295109113191>
- Grodd, W., Kumar, V. J., Schüz, A., Lindig, T., & Scheffler, K. (2020). The anterior and medial thalamic nuclei and the human limbic system: Tracing the structural connectivity using diffusion-weighted imaging. *Scientific Reports*, 10(1), 10957. <https://doi.org/10.1038/s41598-020-67770-4>
- Guillery, R. W. (1966). A study of Golgi preparations from the dorsal lateral geniculate nucleus of the adult cat. *The Journal of Comparative Neurology*, 128(1), 21–50. <https://doi.org/10.1002/cne.901280104>
- Hajdu, F., Hassler, R., & Somogyi, G. (1982). Neuronal and synaptic organization of the lateral geniculate nucleus of the tree shrew, Tupaia glis. *Cell and Tissue Research*, 224(1), 207–223. <https://doi.org/10.1007/BF00217280>

- Hani, S. A., Al-Haidari, M. H., & Saboba, M. M. (2007). Neuronal types in the human anterior ventral thalamic nucleus: A Golgi study. *Cellular and Molecular Neurobiology*, 27(6), 745–755. <https://doi.org/10.1007/s10571-007-9161-1>
- Hazlett, J. C., Dutta, C. R., & Fox, C. A. (1976). The neurons in the centromedian-parafascicular complex of the monkey (*Macaca mulatta*): A Golgi study. *The Journal of Comparative Neurology*, 168(1), 41–73. <https://doi.org/10.1002/cne.901680104>
- Ilinsky, I. A., & Kultas-Ilinsky, K. (2001). Neuroanatomical organization and connections of the motor thalamus in primates. In K. Kultas-Ilinsky & I. A. Ilinsky (Eds.), *Basal ganglia and thalamus in health and movement disorders* (pp. 77–91). Boston, MA: Springer US.
- Jankowski Maciej, M., Ronnqvist Kim, C., Tzanov Marian, Vann Seralynne, D., Wright Nicholas, F., Erichsen Jonathan, T., ... O'Mara Shane, M. (2013). The anterior thalamus provides a subcortical circuit supporting memory and spatial navigation. *Frontiers in Systems Neuroscience*, 7. <http://dx.doi.org/10.3389/fnsys.2013.00045>.
- Kiss, A., & Tömböl, T. (1972). Golgi analysis and degeneration studies of the nucleus ventralis lateralis and ventralis medialis in the cat thalamus. *Brain Research*, 47(2), 303–315. [https://doi.org/10.1016/0006-8993\(72\)90641-5](https://doi.org/10.1016/0006-8993(72)90641-5)
- Kuroda, M., López-Mascaraque, L., & Price, J. L. (1992). Neuronal and synaptic composition of the mediodorsal thalamic nucleus in the rat: A light and electron microscopic Golgi study. *The Journal of Comparative Neurology*, 326(1), 61–81. <https://doi.org/10.1002/cne.903260106>
- Ma, T. P., Lynch, J. C., Donahoe, D. K., Attallah, H., & Rafols, J. A. (1998). Organization of the medial pulvinar nucleus in the macaque. *The Anatomical Record*, 250(2), 220–237. [https://doi.org/10.1002/\(SICI\)1097-0185\(199802\)250:2<220::AID-AR12>3.0.CO;2-Q](https://doi.org/10.1002/(SICI)1097-0185(199802)250:2<220::AID-AR12>3.0.CO;2-Q)
- Morest, D. K. (1975). Synaptic relationships of Golgi type II cells in the medial geniculate body of the cat. *The Journal of Comparative Neurology*, 162(2), 157–193. <https://doi.org/10.1002/cne.901620202>
- Pearson, J. C., & Haines, D. E. (1980). Somatosensory thalamus of a prosimian primate (*Galago senegalensis*). II. An HRP and Golgi study of the ventral posterolateral nucleus (VPL). *The Journal of Comparative Neurology*, 190(3), 559–580. <https://doi.org/10.1002/cne.901900310>
- Rafols, J. A., Aronin, N., & Difiglia, M. A. (1987). Golgi study of the monkey paraventricular nucleus: Neuronal types, afferent and efferent fibers. *The Journal of Comparative Neurology*, 257(4), 595–613. <https://doi.org/10.1002/cne.902570408>
- Saini, K. D., & Garey, L. J. (1981). Morphology of neurons in the lateral geniculate nucleus of the monkey. A Golgi study. *Experimental Brain Research*, 42(3-4), 235–248. <https://doi.org/10.1007/BF00237491>
- Schaltenbrand, G., & Wahren, W. (1977). *Atlas for stereotaxy of the human brain*. Stuttgart: George Thieme Publishers.
- Scheibel, M. E., & Scheibel, A. B. (1966). The organization of the ventral anterior nucleus of the thalamus. A Golgi study. *Brain Research*, 1(3), 250–268. [https://doi.org/10.1016/0006-8993\(66\)90091-6](https://doi.org/10.1016/0006-8993(66)90091-6)
- Somogyi, G., Tömböl, T., & Hajdu, F. (1973). Some Golgi observations in the nucleus anterior ventralis and anterior medialis thalami of the cat. *Zeitschrift für Anatomie und Entwicklungsgeschichte*, 139(3), 247–258. <https://doi.org/10.1007/BF00519967>
- Spreafico, R., Schmechel, D. E., Ellis, L. C., Jr., & Rustioni, A. (1983). Cortical relay neurons and interneurons in the *N. ventralis posterolateralis* of cats: A horseradish peroxidase, electron-microscopic, Golgi and immunocytochemical study. *Neuroscience*, 9(3), 491–509. [https://doi.org/10.1016/0306-4522\(83\)90168-9](https://doi.org/10.1016/0306-4522(83)90168-9)
- Tömböl, T., Ungváry, G., Hajdu, F., Madarász, M., & Somogyi, G. (1969). Quantitative aspects of neuron arrangement in the specific thalamic nuclei. *Acta Morphologica Academiae Scientiarum Hungaricae*, 17(3), 299–313.
- Tömböl, T., Bentivoglio, M., & Macchi, G. (1990). Neuronal cell types in the thalamic intralaminar central lateral nucleus of the cat. *Experimental Brain Research*, 81(3), 491–499. <https://doi.org/10.1007/BF02423497>
- Tseng, G. F., & Royce, G. J. (1986). A Golgi and ultrastructural analysis of the centromedian nucleus of the cat. *The Journal of Comparative Neurology*, 245(3), 359–378. <https://doi.org/10.1002/cne.902450306>
- Wilson, J. R., & Hendrickson, A. E. (1981). Neuronal and synaptic structure of the dorsal lateral geniculate nucleus in normal and monocularly deprived *Macaca* monkeys. *The Journal of Comparative Neurology*, 197(3), 517–539. <https://doi.org/10.1002/cne.901970311>
- Winer, J. A. (1984). The human medial geniculate body. *Hearing Research*, 15(3), 225–247. [https://doi.org/10.1016/0378-5955\(84\)90031-5](https://doi.org/10.1016/0378-5955(84)90031-5)
- Yamamoto, T., Noda, T., Samejima, A., & Oka, H. (1985). A morphological investigation of thalamic neurons by intracellular HRP staining in cats. *The Journal of Comparative Neurology*, 236(3), 331–347. <https://doi.org/10.1002/cne.902360305>
- Yen, C. T., Conley, M., & Jones, E. G. (1985). Morphological and functional types of neurons in cat ventral posterior thalamic nucleus. *The Journal of Neuroscience*, 5(5), 1316–1338. <https://doi.org/10.1523/JNEUROSCI.05-05-01316.1985>
- Zaqout, S. I., Al-Hussain, S. M., Al-Saffar, R. A., & El-Dwairi, Q. A. (2012). A Golgi study of the camel cuneate nucleus. *Anatomical Record (Hoboken)*, 295(12), 2191–2204. <https://doi.org/10.1002/ar.22570>

**How to cite this article:** Al-Hussain SM, Albostanji SA, Mustafa AG, Zaqout S. Neuronal cell types in the anterior ventral thalamic nucleus of the camel. *Anat Rec*. 2021;1–6. <https://doi.org/10.1002/ar.24592>