

Received: 2019.03.28

Accepted: 2019.06.24

Available online: 2020.01.24

Published: 2020.02.02

# An Unusual Case of Modified Lemierre's Syndrome Caused by *Staphylococcus aureus* Cellulitis

Authors' Contribution:

Study Design A

Data Collection B

Statistical Analysis C

Data Interpretation D

Manuscript Preparation E

Literature Search F

Funds Collection G

ABCDEF 1 **Israa A. Elhakeem**  
EG 1 **Shaikha D. Al Shokri**  
E 2,3,4 **Abdul-Naser Y. Elzouki**  
DEFG 5,6 **Mohammed I. Danjuma**

1 Department of Internal Medicine, Hamad Medical Corporation, Doha, Qatar

2 Department of Internal Medicine, Hamad General Hospital, Doha, Qatar

3 Department of Clinical Medicine, Qatar University, Doha, Qatar

4 Weill Cornell Medicine, Doha, Qatar

5 Clinical Pharmacology and Therapeutics Department of General Medicine, Hamad

General Hospital, Doha, Qatar

6 Department of Clinical Medicine, Weill Cornell Medicine, Doha, Qatar

**Corresponding Author:** Israa A. Elhakeem, e-mail: [israa\\_965@hotmail.com](mailto:israa_965@hotmail.com)**Conflict of interest:** None declared

**Patient:** Male, 31-year-old  
**Final Diagnosis:** Lemierre's Disease  
**Symptoms:** Conjunctival injection • eye pain and redness • fever • nasal swelling • periorbital oedema • ptosis • vesicular lesions nose  
**Medication:** —  
**Clinical Procedure:** None  
**Specialty:** Infectious Diseases

**Objective:** Rare disease  
**Background:** Lemierre's syndrome is a potential life-threatening disease commonly occurring in young, healthy individuals. It is often preceded by an oropharyngeal infection causing bacteremia. This may rapidly progress into thrombophlebitis of the internal jugular venous system, its branches, and septic embolization and often fulminant organ failure.

**Case Report:** A previously healthy 31-year-old male with recent history of facial herpes zoster infection, presented with 1-week history of increasingly painful nasal, and periorbital swelling. Imaging confirmed superior ophthalmic vein thrombosis. *Staphylococcus aureus* was isolated in blood cultures and had an uncomplicated hospital course with full recovery.

**Conclusions:** Early recognition of Lemierre's syndrome contributes significantly in reducing morbidity and mortality associated with it. *Staphylococcus aureus* skin infection is a very rare cause of Lemierre's syndrome, and its association with superior ophthalmic vein thrombosis has not yet been reported in literature.

**MeSH Keywords:** Herpes Zoster • Lemierre Syndrome • *Staphylococcus aureus* • Venous ThromboembolismFull-text PDF: <https://www.amjcaserep.com/abstract/index/idArt/916575>

1941



2



3



24

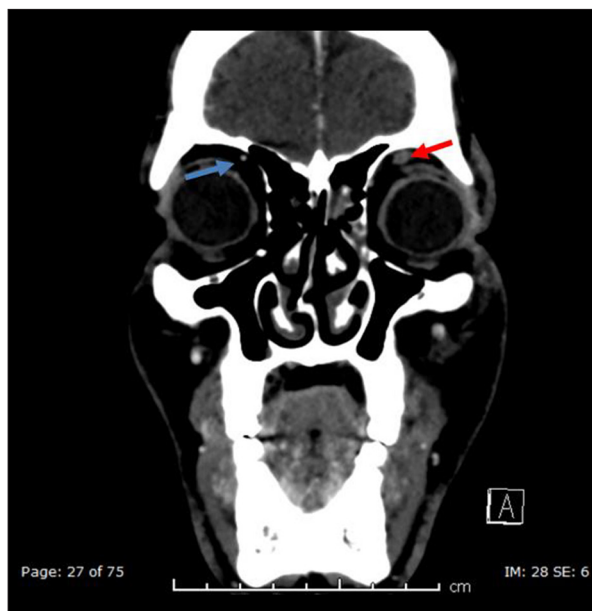


## Background

Lemierre's syndrome, also known as the "forgotten disease" is a rare entity typically characterized by thrombosis of the internal jugular vein and its tributaries. This very often follows an oropharyngeal infection [1]. First described by the Frenchman Andre Lemierre in 1936, it is considered to be rare with a reported incidence of about 0.8 million cases per year [1]. It usually occurs in otherwise healthy individuals in their second decade, with a disproportionately high male preponderance [2]. Complications can be life threatening in cases without early intervention. These include overwhelming bacteremia, malignant cellulitis, metastatic abscesses, and septic emboli (with special predilection for the lungs) [2]. Although, in 90% of reported Lemierre's syndromes the causative agent is the anaerobic oral commensal *Fusobacterium necrophorum* [3], other *Fusobacterium* species, some anaerobes, *Streptococci*, and *Staphylococcus aureus* (both methicillin-sensitive *Staphylococcus aureus* [MSSA] and methicillin-resistant *Staphylococcus aureus* [MRSA]) have also been reported [4]. Diagnostic criteria for classical Lemierre's syndrome include positive blood cultures, and radiological evidence of internal jugular vein thrombophlebitis [5]. We report a case of a young male patient with history of recent herpes zoster infection who presented with orbital cellulitis secondary to malignant *Staphylococcus aureus* facial infection. This subsequently caused superior ophthalmic vein thrombosis as part of his other clinical sequelae. He was treated early with intravenous antibiotics, antiviral agents, and an early strategy of anticoagulation to prevent debilitating complications.

## Case Report

A 31-year-old healthy male presented to the emergency department with a week's history of increasing redness and left-sided nose swelling that gradually involved his left eye. A few days prior to the onset of his current symptoms, he had developed a painful blistering rash on his left anterior nares, which was managed as herpes zoster exanthema. On examination, he looked in pain, there was left upper eyelid swelling with ptosis. He additionally had erythematous crusting with vesicular lesions on the lateral aspect of nose, as well as mild conjunctival injection. There were no cranial nerve deficits, and the rest of his neurological, cardio-respiratory, and abdominal examinations were unremarkable. Herpetic ocular involvement was ruled out by fluorescein examination. He was afebrile, with a saturation of 100% on room air, pulse rate of 88 beats per minute, and blood pressure of 136/78 mm Hg. Electrocardiogram (ECG) showed normal sinus rhythm. Initial biochemistry was significant for leukocytosis with a white blood cell count of  $15.7 \times 10^3/\mu\text{L}$ , and an absolute neutrophil count of  $12 \times 10^3/\mu\text{L}$ . C-reactive protein (CRP) was elevated at 269.1 mg/L.

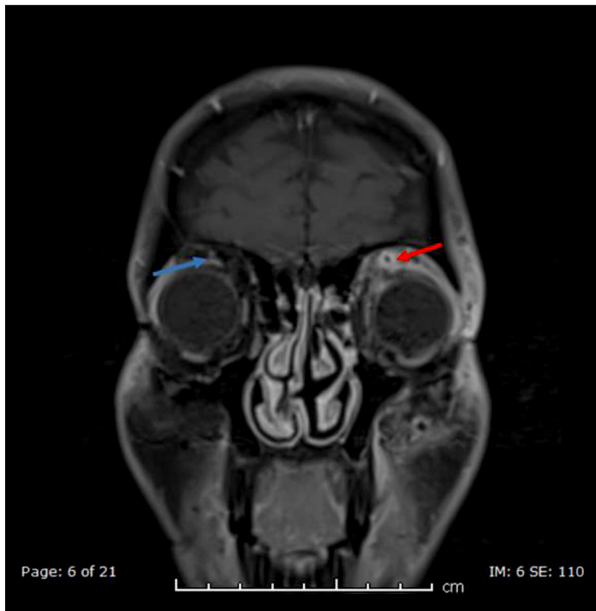

**Figure 1.** Computed tomography post contrast coronal imaging showing left sided (red arrow) superior ophthalmic filling defect suggestive of venous thrombosis.

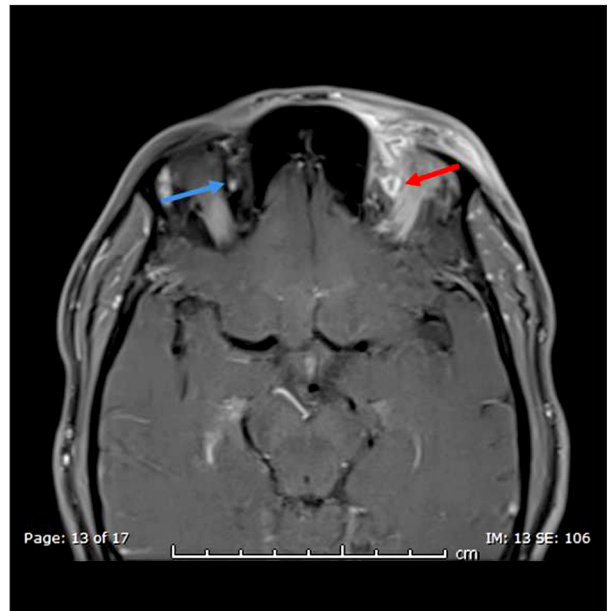
Other electrolytes including kidney, liver, and coagulation profiles were within normal limits. Chest x-ray showed clear lung fields. Computed tomography (CT) of both orbits and facial bones (Figure 1) were suggestive of cellulitis in left periorbital region extending to the left nasal bone, the maxilla, left side of his face, as well as partial thrombosis of left facial vein. He was commenced empirically on intravenous (IV) meropenem, and acyclovir. On the second day of admission, he started to spike a high-grade fever of 38.4°C accompanied by tachycardia (124 beats per minute). Initial blood and skin pustule aspirate cultures grew methicillin sensitive *Staphylococcus aureus*. Echocardiogram ruled out valvular vegetations or heart valve thrombosis. Subsequent magnetic resonance imaging (MRI)/magnetic resonance venography (MRV) of his orbits with contrast (Figures 2, 3) confirmed left-sided periorbital and pre-septal soft tissue swelling, retro-orbital fat stranding, and left superior ophthalmic vein thrombosis. Over the next couple of days his vital parameters returned to baseline. On day 5, he was switched to IV cloxacillin, to complete a total antibiotic course of 4 weeks duration. Anti-coagulation was also initiated to reduce the risk of recurrent venous thromboembolism (VTE) with initial low molecular weight heparin, which was ultimately transitioned to warfarin for 3 months. Table 1 gives the clinical course of his hospital stay

## Discussion

Anaerobic post anginal septicemia was Andre Lemierre's first definition of this disease in 1936 [15] after publishing a series



**Figure 2.** Magnetic resonance imaging T1 post contrast, coronal view showing left sided (red arrow) superior ophthalmic filling defect consistent with venous thrombosis.



**Figure 3.** Magnetic resonance imaging T1 post contrast, axial view showing left sided (red arrow) superior ophthalmic filling defect.

**Table 1.** An overview of the clinical course of his hospital stay with kinetics of key biochemical parameters as a function of antimicrobial therapy.

Antibiotic day	Temperature °C (oral)	WBC ( $10.1 \times 10^3/\mu\text{L}$ )	CRP (mg/L)
1	36.9	15.7	269
2	38.4	–	–
4	37	–	62
6	36.9	10.1	–
15	36.8	8	–
28	37	7.2	–

WBC – white blood cell; CRP – C-reactive protein.

of 20 cases in which anaerobic sepsis was preceded by a throat infection. We currently recognize the disease as an oropharyngeal infection followed by septicemia, thrombophlebitis at the primary site of infection, and distant metastatic abscesses due to migrating septic thrombotic plaques [16]. It is assumed that an increase in factor VIII may be a key contributing factor in thrombosis of these patients. In the pre-antibiotic era, Lemierre's syndrome had a reported mortality rate of approximately 100% [1]. While the basic phenotype of the disease has remained largely the same, there has been considerable reduction in both morbidity and mortality associated with it.

In this report we have discussed an atypical presentation and a rare clinical course of Lemierre's syndrome both in the microbiological agent involved (*Staphylococcus aureus*) as well

as the disposition of venous thrombosis (superior ophthalmic vein thrombosis). The latter probably due to super-imposed infection of nasal herpetic lesions. The clinical course of our patient including morbidity parameters such as microbiological response, and length of hospital stay fits within the ballpark reported from recent reports. Our patient's initial complaint of facial swelling and orbital pain is very interesting, as orbital pain as the key index presentation is variable from most recent reports [17]. To compare the clinical course of our patient in the context of other reports, we reviewed a series of current literature and recent presentations (especially atypical blood culture isolates, as well as territory of venous system thrombosis involved). This is given in Table 2. In a report by Karkos et al., for example, analyzing case reports from 1940 to 2007, only 1% of the cases had orbital pain as an initial

**Table 2.** An overview of blood culture isolates as a function of differential veno-thrombotic territory.

Study (reference)	Year	Gender	Territory of venous system thrombosis	Blood culture isolate
Takiguchi et al. [6]	2017	Female	Left external jugular	Group C Streptococcus
Kadhiravan et al. [7]	2008	Female	Right internal jugular extending to superior vena cava	Community acquired methicillin resistant <i>Staphylococcus aureus</i>
Boga et al. [8]	2007	Male	Right internal jugular Splenic vein	<i>Staphylococcus aureus</i>
Singaporewalla et al. [9]	2006	Male	Left internal jugular	<i>Klebsiella pneumonia</i>
Stauffer et al. [10]	2012	Female	Bilateral cavernous sinus and ophthalmic vein thromboses	Community acquired methicillin resistant <i>Staphylococcus aureus</i>
Shivashankar [11]	2008	Male	Cavernous sinus extending to left internal jugular	Panton-Valentine leucocidin-producing <i>Staphylococcus aureus</i>
Tsai et al. [12]	2014	Female	Left internal jugular vein extending to sigmoid sinus	<i>Klebsiella pneumonia</i>
Krishna et al. [4]	2012	Male	Left lateral sigmoid sinus Left internal jugular	<i>Staphylococcus aureus</i>
Agawaral et al. [13]	2013	Male	Right internal jugular extending to subclavian	Methicillin resistant <i>Staphylococcus aureus</i>
Etienne et al. [14]	2008	Female	Right internal and external jugular	<i>Staphylococcus aureus</i>

presentation [17]. The territory of associated venous thromboembolism in this report also showed a remarkably low involvement of venous systems other than the internal jugular vein. Out of 86 case reports reviewed for example, only 1 was complicated by superior ophthalmic vein thrombosis. The novelty of our patient presentation with superior ophthalmic vein thrombosis adds to increasing incidence of venous systems involvement outside of the internal jugular venous system. While the exact explanation for this remains debatable, the preponderance of the primary focus of infection/inflammation may perhaps offer an insight into the mechanism thromboembolism in these cohorts of patients. There was no reported case caused by *Staphylococcus aureus* prior to this series [17]. To the best of our knowledge, there has not been a reported case of super-imposed herpetic lesions causing Lemierre's syndrome.

The exact role of other agents such as *Staphylococcus aureus* has evolved over the years. Only recently has *Staphylococcus aureus* been identified as a plausible cause of Lemierre's syndrome with most isolates growing either methicillin resistant *Staphylococcus aureus* or Panton-Valentine Leucocidin (PVL) toxin producers [18]. It is an opportunistic organism that colonizes skin and soft tissue. The mechanism of bypassing the immune response following staphylococcal infection, has been suggested to be primarily neutrophilic and phagocytic. It accomplishes resisting destruction after being ingested by a phagocyte, inhibit leukocytic chemotaxis, evade hosts antibodies, and utilizing its polysaccharide capsule conceal itself from the hosts detection system [19] The PVL toxin is

particularly virulent and is considered to be one of the most severe toxins produced, with a robust ability to lyse human white blood cells [19].

Most of the initial and by far a significant proportion of reports of Lemierre's syndrome were associated with *Fusobacterium necrophorum* as the causative organism in two-thirds of the cases. Other organisms are considered atypical and *Staphylococcus aureus* is still considered to be a rare cause [20]. The skin has been suggested to be the commonest site for primary staphylococcal infection in this cohort of patients [21]. In one study, 40% of patients from an outpatient setting had *Staphylococcus aureus* colonization in their nasal carriage with the risk of potential overt bacteremia and its attendant complications [22]. In a presentation similar to ours, Chanin et al. reported an immuno-competent individual that eventually had bacteremia but with a more adverse clinical course [20]. This presumably was due to the patient's late presentation, and a methicillin-resistant *Staphylococcus aureus* (MRSA) isolate. Similarly, Kadhiravan et al. [23], reported a young healthy individual admitted with orbital cellulitis (similar to our case), however, as was the case with previously described reports (including Chanin et al. [20]), this patient's clinical course was rather complicated. Probably explanation suggested for this stormy clinical course includes septic embolism to her lungs, and bacteremia consistent with community acquired methicillin resistant *Staphylococcus aureus* (MRSA). Despite its previously reported rarity, there have been increasing reports of orbital cellulitis as the index presentation in these

cohorts of patients [23]. Kadiravan et al. for example reported a case of a patient who presented with an incident painful eye swelling that was subsequently found confirmed to have orbital cellulitis on further imaging studies [23]. In comparison, Shivashankar et al. reported on a similar case whose initial periorbital swelling was accompanied by multiple cranial nerve deficits due to migrating septic thrombophlebitis to the cavernous sinus with attendant multiple brain infarction [11].

The exact location of venous thromboembolism in these cohorts of patients has also attracted considerable interest. Although the initial site of the first report [1] appears to be the internal jugular vein, further propagation has varied in subsequent reports since. The most common area of thrombus propagation in the venous territory is superiorly from the internal jugular veins to sigmoid and cavernous sinuses and inferiorly to the subclavian vein [24] Propagation to the superior branch of ophthalmic vein has not yet been reported in current literature to the best of our knowledge.

How initial or associated viral exanthema such herpes zoster contributes to or predispose vulnerable patients to Lemierre's syndrome remains uncertain. Among the few that have reported on this includes Etienne et al. [14] whose patient presentation, clinical course, patient demography (young, immunocompetent), and microbiological isolate (*Staphylococcus aureus*) bore resemblance to our case. The typical duration of antimicrobial therapy is 4 to 6 weeks, while the need and the exact strategy for anti-coagulation still remains a matter for ongoing debate (with administration in only 20% to 30% of documented case reports). In our patient, we continued IV antibiotics for a duration of 4 weeks and anticoagulation from low molecular weight heparin to warfarin for 3 months.

What has, however, remained unresolved is both the apparent and real increase in incidence of this syndrome. A plausible explanation might be due to increasing vigilance from improving awareness about this entity. Other factors may include, increasing reluctance for empirical antibiotic therapy in

patient's presenting with evolving staphylococcal skin infections due to the ever-increasing demands of antibiotic stewardship. Other factors include improved diagnostic capacity of recent generation CT and MRI scanners at resolving sub-clinical incidental clots that may have been unapparent on earlier generation scanners.

### Limitations

One of the major limitations of our report was the inability to obtain the exact strain of *Staphylococcus aureus*. We suspect that the phenotype, and clinical course of our patient suggests that the *Staphylococcus aureus* isolated was probably a PVL toxin producing variety. Additionally, we were unable to ascertain the exact role of concomitant herpes zoster infection our patient had prior to hospital presentation to his ultimate definitive diagnosis of Lemierre's syndrome.

### Conclusions

*Staphylococcus aureus* skin infection is a very rare cause of Lemierre's syndrome, and superior ophthalmic vein thrombosis has not yet been reported in literature. It is important to acknowledge the potential risk of superadded infection of herpes zoster. Early recognition of Lemierre's syndrome contributes significantly in reducing its morbidity and mortality.

### Lessons and future perspectives

As clinicians we must always consider both classical and modified presentations of this syndrome in the setting of facial cellulitis with a bacterial isolate, due to the additional possibilities of morbidity that may need treatment such as associated venous thromboembolisms.

### Conflict of interest

None.

### References:

1. Sibaj K, Surasin F: Lemierre syndrome. A diagnosis to keep in mind. Rev Med Suisse Romande, 2004; 124: 693–95
2. Kristensen LH, Prag J: Human necrobacillosis, with emphasis on Lemierre's syndrome. Clin Infect Dis, 2000; 31: 524–32
3. Dee P, Berman D: Lemierre syndrome – infectious disease and antimicrobial agents. [online] Antimicrobe.org. Available at: <http://www.antimicrobe.org/e56.asp>
4. Krishna K, Diwan A, Gupta A: Lemierre's Syndrome – the syndrome quite forgotten. The Journal of the Associations of Physicians of India, 2012; 60: 60–63
5. Zhao A, Samannodi M, Tahir M et al: Lemierre's syndrome: Case report and brief literature review. ID Cases, 2017; 27: 15–17
6. Takiguchi J, Sakamoto H, Inoue N: Lemierre's syndrome variant with external jugular vein thrombosis. Intern Med, 2017; 56: 1271–72
7. Kadiravan T, Piramanayagam P, Banga A et al: Lemierre's syndrome due to community-acquired methicillin-resistant *Staphylococcus aureus* infection and presenting with orbital cellulitis: A case report. J Med Case Rep, 2008; 2: 374
8. Boga C, Hakan O, Banu D et al: Lemierre's syndrome variant: *Staphylococcus aureus* associated with thrombosis of both the right internal jugular vein and the splenic vein after the exploration of a river cave. J Thromb Thrombolysis, 2007; 23: 151–54
9. Singaporewalla R, Clarke M, Krishnan P, Tan D: Is this a variant of Lemierre's syndrome? Singapore Med J, 2006; 47: 1092–95
10. Stauffer C, Josiah AF, Fortes M et al: Lemierre syndrome secondary to community-acquired methicillin-resistant *Staphylococcus aureus* infection associated with cavernous sinus thromboses. J Emerg Med, 2013; 44: 177–82

11. Shivashankar GH, Murukesh N, Varma MP et al: Infection by Panton-Valentine leukocidin-producing *Staphylococcus aureus* clinically mimicking Lemierre's syndrome. *J Med Microbiol*, 2008; 57: 118–20
12. Tsai Y, Lin Y, Harnnd D et al: A Lemierre syndrome variant caused by *Klebsiella pneumoniae*. *J Formos Med Assoc*, 2012; 111: 403–5
13. Abhishek A, Sandeep S, Tarun P: Lemierre syndrome from a neck abscess due to methicillin-resistant *Staphylococcus aureus*. *Braz J Infect Dis*, 2013; 17: 507–9
14. Puymirat E, Biais M, Camou F et al: A Lemierre syndrome variant caused by *Staphylococcus aureus*. *Am J Emerg Med*, 2008; 26: 380.e5–e7
15. Chacko E, Krilov L, Patten W, Lee P: Lemierre's and Lemierre's-like syndromes in association with infectious mononucleosis. *J Laryngol Otol*, 2010; 124: 1257–62
16. Farhan A, Shah Y, Ali B et al: The forgotten disease – Lemierres syndrome. *J Pak Med Assoc*, 2016; 66: 1652–55
17. Karkos P, Asrani S, Karkos C et al: Lemierre's syndrome: A systematic review. *Laryngoscope*, 2009; 119: 1552–59
18. Molloy A, Towersey G, Shackleton D et al: The changing face of an old disease: case report of nonclassical Lemierre's syndrome caused by a panton-valentine leukocidin positive methicillin-susceptible *Staphylococcus aureus* isolate. *J Clin Microbiol*, 2012; 50: 3144–45
19. Tong S, Davis J, Eichenberger E et al: *Staphylococcus aureus* infections: Epidemiology, pathophysiology, clinical manifestations, and management. *Clin Microbiol Rev*, 2015; 28: 605–61
20. Chanin J, Marcos L, Thompson B et al: Methicillin-resistant *Staphylococcus aureus* USA300 clone as a cause of Lemierre's syndrome. *J Clin Microbiol*, 2011; 49: 2063–66
21. Miller L, Kaplan S: *Staphylococcus aureus*: A community pathogen. *Inf Dis Clin North Am*, 2009; 23: 35–52
22. Eiff C, Becker K, Machka K et al: Nasal carriage as a source of *Staphylococcus aureus* bacteremia. *N Engl J Med*, 2001; 344: 11–16
23. Kadiravan T, Piramanayagam P, Banga A et al: Lemierre's syndrome due to community-acquired methicillin-resistant *Staphylococcus aureus* infection and presenting with orbital cellulitis: A case report. *J Med Case Rep*, 2008; 2: 374
24. Nickson C: Lemierre's syndrome. Life in the Fast Lane (LITFL) Medical Blog. [online]. Available at: <https://lifeinthefastlane.com/cc/lemierres-syndrome/>